

CASE CONFERENCE

Supervisor: 常傳訓主任

Reporter: PGY 謝孟廷

104-12-12

CASE 1

PATIENT'S PROFILE

- Chart No. xxxxxxxx
 - Name: OOO
 - Gender: Female
 - Age: 64 Y/O
 - Admission date: 2015/07/15 – 2015/07/25
-

PRESENT ILLNESS

- Admitted due to severe back pain for over 20 days prior to this admission.
- L2 compression fracture post vertebroplasty on 2011/04/25 and adjacent fracture at L1, 3 was noted when followed up at NS OPD.
- **L4 compression** was diagnosed this time and vertebroplasty was planned for her.
- **Neutropenic fever** was noted before the vertebroplasty.
- Refer to Dr. 常傳訓

2015/07/15 18:43

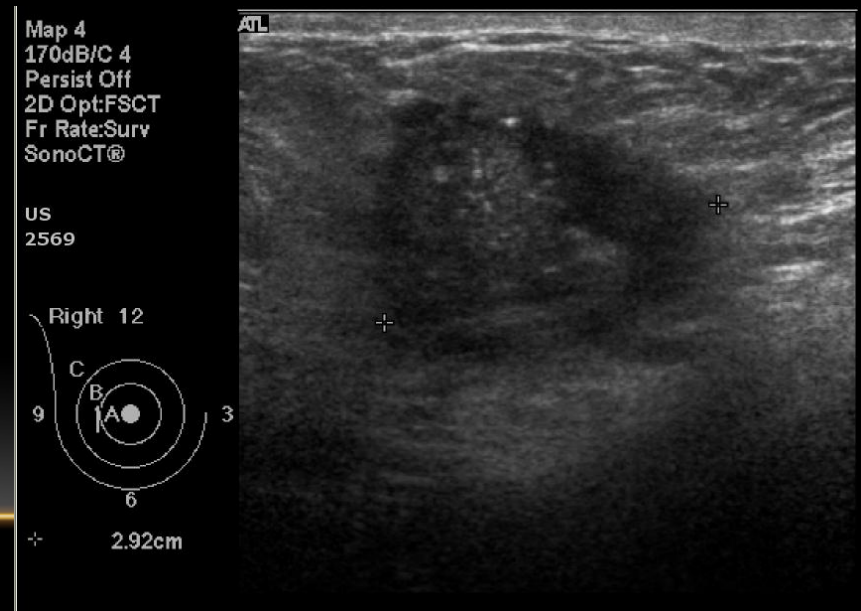
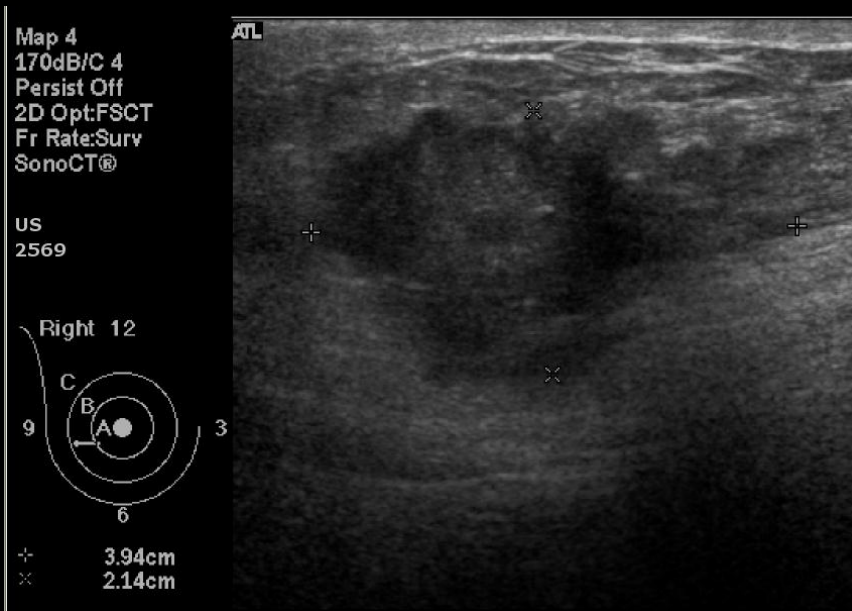
2015/07/15 21:54

CBC				
WBC	LL	0.6	10 ³ /uL	4.0 - 10.0
備註： ※ 超過危險值範圍				
RBC	L	2.42	10 ⁶ /uL	3.70 - 5.50
HGB	L	7.3	g/dL	11.3 - 15.3
HCT	L	21.7	%	33.0 - 47.0
MCV		89.7	fL	80.0 - 100.0
MCH		30.2	pg	25.0 - 34.0
MCHC		33.6	g/dL	30.0 - 36.0
PLT		304	10 ³ /uL	130 - 400
DIFF				
NEUT%	L	4.0	%	40.0 - 75.0
LYMPH%	H	77.0	%	20.0 - 45.0
MONO%		7.0	%	2.0 - 10.0
EO%		6.0	%	1.0 - 6.0
BASO%		0.0	%	0 - 1
ATYPICAL LYMPH		6.0	%	
COMMENT		檢體已重測兩次.		

CBC				
WBC	LL	0.9	10 ³ /uL	4.0 - 10.0
備註： ※ 超過危險值範圍				
RBC	L	2.45	10 ⁶ /uL	3.70 - 5.50
HGB	L	7.2	g/dL	11.3 - 15.3
HCT	L	22.3	%	33.0 - 47.0
MCV		91.0	fL	80.0 - 100.0
MCH		29.4	pg	25.0 - 34.0
MCHC		32.3	g/dL	30.0 - 36.0
PLT		273	10 ³ /uL	130 - 400
DIFF				
NEUT%	L	1.1	%	40.0 - 75.0
BAND		1.1	%	
LYMPH%	H	90.5	%	20.0 - 45.0
MONO%		7.4	%	2.0 - 10.0
EO%	L	0.0	%	1.0 - 6.0
BASO%		0.0	%	0 - 1
Giant Platelet	*	Positive		

HISTORY

- 2014/10/14
 - First time to our OPD due to a **palpable mass** of right outer breast.
 - Mammogram and breast sonogram were done



- 2014/10/17
 - Core needle biopsy
 - right outer advanced breast **invasive ductal carcinoma**
 - 2014/10/21
 - Right axillary lymph node biopsy
 - right axillary lymph nodes **metastases**
 - 2014/12/01
 - Left Port-A implantation
 - Neoadjuvant chemotherapy Taxotere + Herceptin
-

- 2014/12/19
 - Patient refused Taxotere treatment due to nausea and vomiting with neutropenia infection
→ Oral Navelbine + Herceptin
- Side effect of chemotherapy
 - ECOG:1, 噁心:G1, 嘔吐:G1, 腹瀉:G1, 口腔黏膜炎:G1, 皮膚反應:G1, 指甲反應:G1, 疲憊:G2, 掉髮:G1, 週邊神經感覺症狀:G1

MANAGEMENT

- Neutropenic fever
 - Consult infection and antibiotic treatment
- Neutropenia
 - Filgrastim (G-CSF)
 - WBC transfusion 2U x 2days and whole blood transfusion 2U
- Thrombocytopenia
 - Platelet transfusion 2U x 2days

2015/07/18

2015/07/20

CBC				
WBC	LL	0.6	10 ³ /uL	4.0 - 10.0
備註： ※ 超過危險值範圍				
RBC		3.93	10 ⁶ /uL	3.70 - 5.50
HGB		11.8	g/dL	11.3 - 15.3
HCT		33.8	%	33.0 - 47.0
MCV		86.0	fL	80.0 - 100.0
MCH		30.0	pg	25.0 - 34.0
MCHC		34.9	g/dL	30.0 - 36.0
PLT		200	10 ³ /uL	130 - 400

WBC	LL	0.5	10 ³ /uL	4.0 - 10.0
備註： ※ 超過危險值範圍				
RBC		3.94	10 ⁶ /uL	3.70 - 5.50
HGB		12.0	g/dL	11.3 - 15.3
HCT		33.9	%	33.0 - 47.0
MCV		86.0	fL	80.0 - 100.0
MCH		30.5	pg	25.0 - 34.0
MCHC		35.4	g/dL	30.0 - 36.0
PLT		168	10 ³ /uL	130 - 400
DIFF				
NEUT%	L	5.9	%	40.0 - 75.0
LYMPH%	H	82.4	%	20.0 - 45.0
MONO%		5.9	%	2.0 - 10.0
EO%	L	0.0	%	1.0 - 6.0
BASO%		0.0	%	0 - 1
META		2.0	%	
ATYPICAL LYMPH		3.9	%	
Giant Platelet	*	Positive		

2015/07/22

2015/07/24

CBC				
WBC		8.1	10 ³ /uL	4.0 - 10.0
RBC		3.89	10 ⁶ /uL	3.70 - 5.50
HGB		11.6	g/dL	11.3 - 15.3
HCT		33.3	%	33.0 - 47.0
MCV		85.6	fL	80.0 - 100.0
MCH		29.8	pg	25.0 - 34.0
MCHC		34.8	g/dL	30.0 - 36.0
PLT		162	10 ³ /uL	130 - 400
DIFF				
NEUT%		40.9	%	40.0 - 75.0
BAND		28.2	%	
LYMPH%	L	8.2	%	20.0 - 45.0
MONO%	H	19.1	%	2.0 - 10.0
EO%	L	0.0	%	1.0 - 6.0
BASO%		0.0	%	0 - 1
META		2.7	%	
ATYPICAL LYMPH		0.9	%	
COMMENT		檢體已重測兩次.		

CBC				
WBC	H	27.3	10 ³ /uL	4.0 - 10.0
RBC		3.96	10 ⁶ /uL	3.70 - 5.50
HGB		11.9	g/dL	11.3 - 15.3
HCT		34.2	%	33.0 - 47.0
MCV		86.4	fL	80.0 - 100.0
MCH		30.1	pg	25.0 - 34.0
MCHC		34.8	g/dL	30.0 - 36.0
PLT		165	10 ³ /uL	130 - 400
DIFF				
NEUT%	H	75.7	%	40.0 - 75.0
BAND		2.8	%	
LYMPH%	L	3.7	%	20.0 - 45.0
MONO%	H	14.0	%	2.0 - 10.0
EO%	L	0.0	%	1.0 - 6.0
BASO%		0.0	%	0 - 1
NRBC%		0.9	/100WBC	
META		2.8	%	
ATYPICAL LYMPH		0.9	%	

CASE 2

PATIENT'S PROFILE

- Chart No. xxxxxxxx
 - Name: OOO
 - Gender: Female
 - Age: 84 Y/O
 - Admission date: 2013/12/04 – 2013/12/16
-

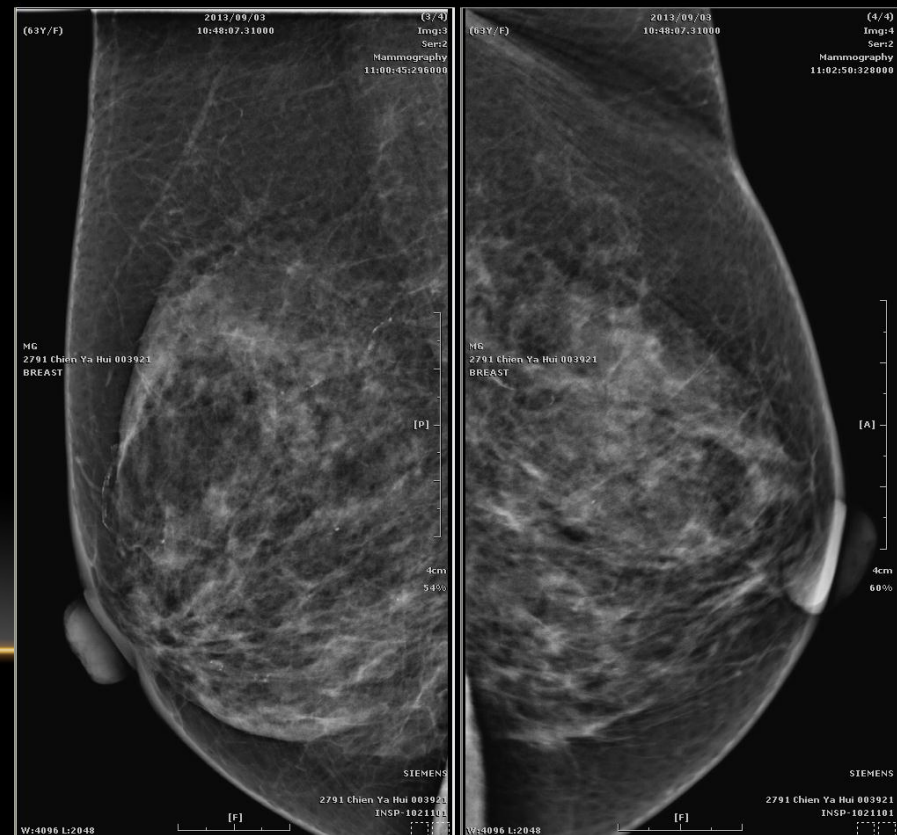
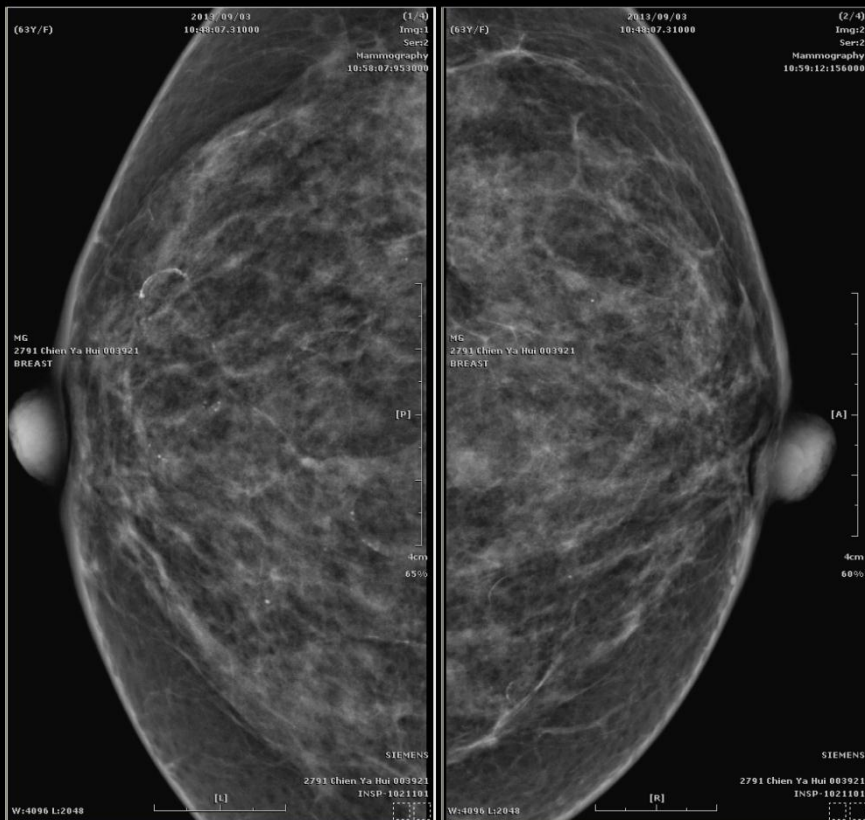
- Right breast cancer
 - 6 o'clock **ductal carcinoma in situ (DCIS)** with diffuse microcalcification
 - cT1sN0M0, **stage 0**
 - ER 95%(+), PR 75%(+)
→ Hormone therapy with Tamoxifen
 - Left breast lesion
 - 7 o'clock 0.92x0.47 cm
 - 11 o'clock 1.44x1.41x0.67 cm irregular
→ CNB
-

- **End stage renal disease (ESRD) with uremia** under regular hemodialysis (QW1, 3,5) for over 5 years.
 - Intracranial hemorrhage post V-P shunt implants on 2010/02/09 at XX hospital.
 - Old stroke with dementia (hemiplegia, left)
 - Seizure disorder
 - Chronic liver disease
-

HISTORY

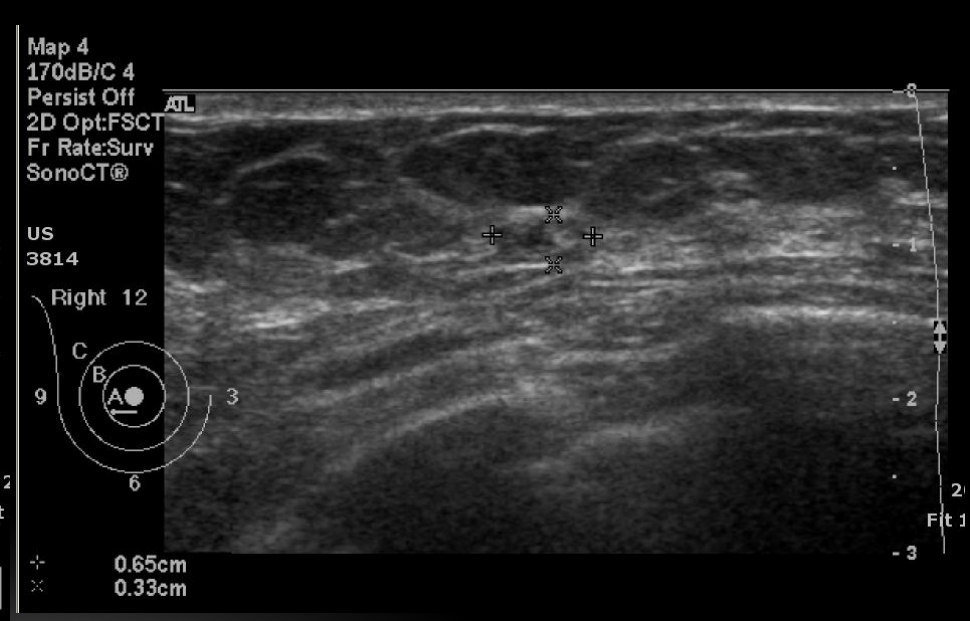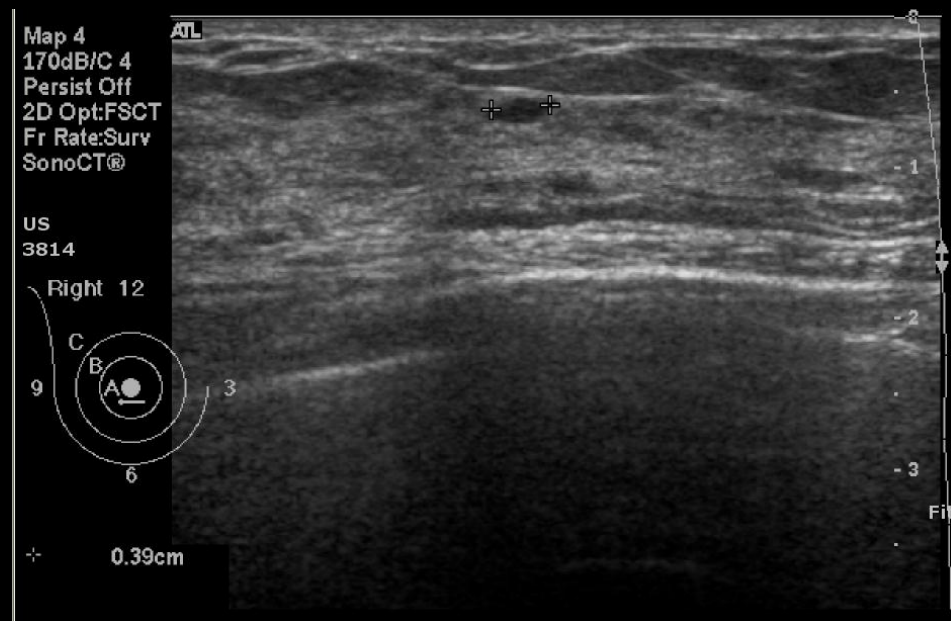
- Refer from 國健局 on 2012/12
 - Abnormal mammogram findings, BI-RADS 4
→ right breast 6 o'clock cluster calcification
 - Breast sonogram
 - Right
 - 2 o'clock 0.40cm
 - 6 o'clock 0.95x0.65x0.33cm with microcalcification, 0.39cm → CNB
 - 9 o'clock 0.80x0.74x0.36cm
 - Left
 - 7 o'clock 0.92x0.47cm
 - 11 o'clock 1.44x1.41x0.67cm, irregular → CNB

- 2013/09/03 Mammogram
 - Heterogeneously dense breast tissue
 - Calcifications in both breasts
 - **BI-RADS category 0**, need additional examination

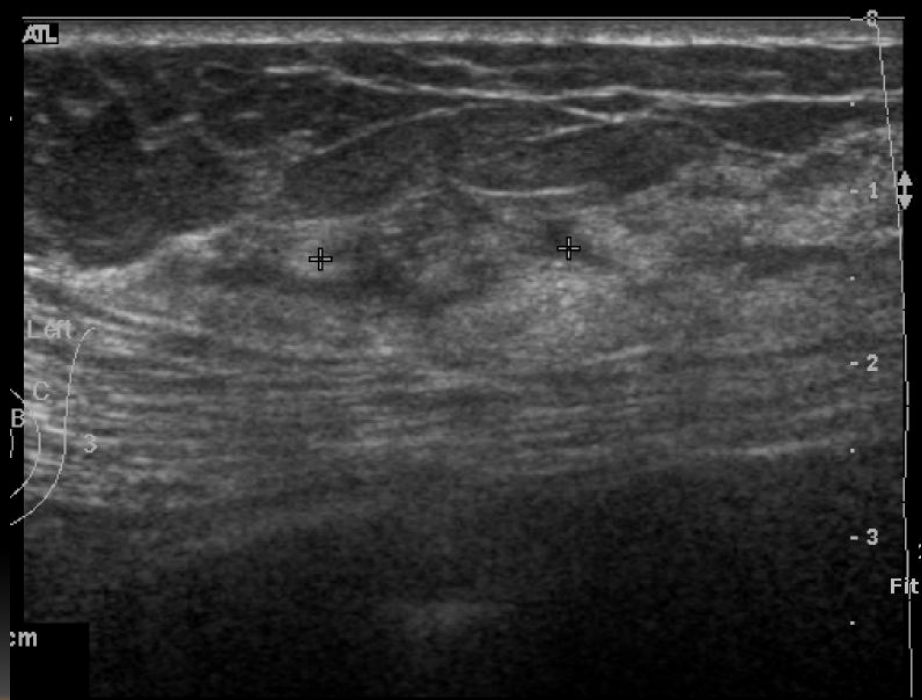
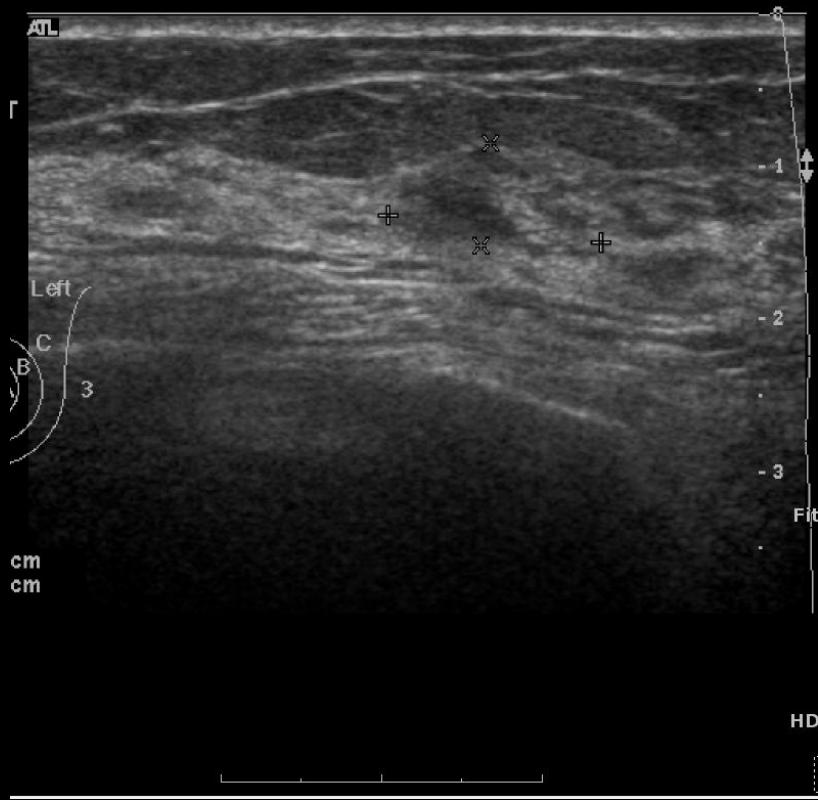


- 2013/11/27 Breast sonogram

- Right: A 0.39x0.65x0.33 cm lobulated hypoechoic nodule at 6-7 o'clock direction.



- Left lobulated hypoechoic nodule 1.4x0.6 cm at 12 o'clock direction.



- Surgery on 2013/12/05:
 - Right breast **total mastectomy** and right axillary **sentinel lymph nodes biopsies**.
 - Left breast 11 o'clock 1.44x1.41x0.67cm lesion excision.
-

